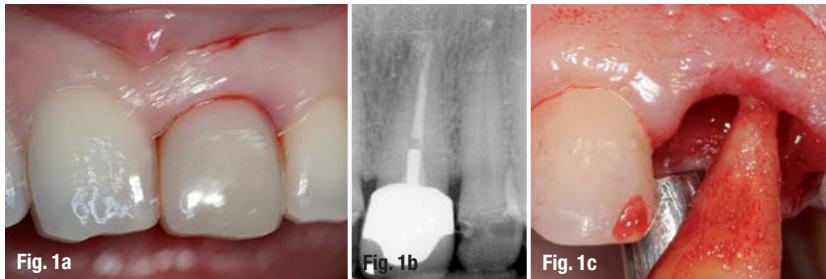


Immediate implantation in the anterior maxilla

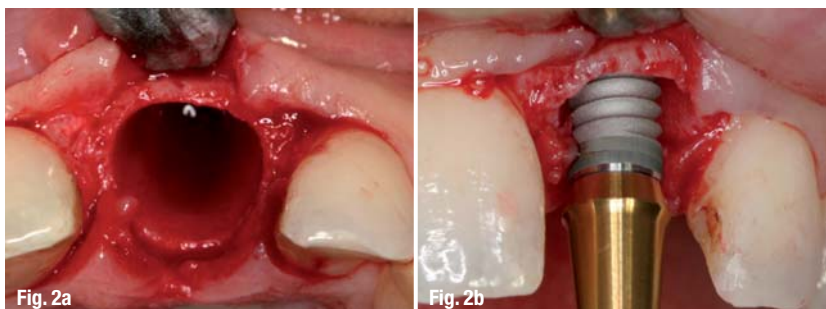
Planning in reverse

Authors_Dr Nikolaos Papagiannoulis, Dr Olaf Daum, Dr Eduard Sandberg & Dr Marius Steigmann, Germany



_Introduction

Endodontic and periodontal problems, such as surgical complications, often place before the professional the dilemma of choosing between tooth preservation and extraction. Correctly performed root planing usually leads to soft-tissue recession. In cases of tooth mobility, periodontal surgery can improve the situation only in the short term. Tooth loss eventually follows after some months or years, not to mention the aesthetic disadvantages of flap elevation and tissue excision after periodontal surgical treatment. Similar outcomes are predicted for teeth following endodontic treatment, particularly if they show complications or have undergone root resection. The combination of endodontic and periodontal problems, as with periodontal-endodontic lesions, endangers the tooth, as well as the bone and the anatomy of the jaw. Lesions such as these can result in severe defects, hampering any subsequent treatment with prostheses.¹



The question one ought to be asking is whether a tooth in the aesthetic zone should be treated until all treatment options have been exhausted or whether the extraction of this tooth at the right time could increase the success and aesthetic outcome of the implant treatment. The extraction of a tooth in the aesthetic zone immediately solves the inflammation problem, but the difficulties only begin at this point. There are many aspects to take care of in order to achieve aesthetic success. Analysis of hard and soft tissue, the implant system, time of implantation, flap design and closure of the area, implant position, implant dimensions, temporary treatment and prostheses are all factors that influence the treatment outcome massively.

_Case history

A 34-year-old female patient visited our practice two years ago, with complaints about her maxillary central incisor (tooth #21). The tooth had been treated endodontically eight years before. Five years later, the tooth had been retreated owing to complaints and she had undergone root resection a year later. Afterwards, an intra-radicular post and a metal ceramic crown had been placed.

At the time of the patient's first visit, the tooth was mobile, bled from the periodontal gap during brushing and caused pain, resulting in headaches. Considering the extended period for which the patient had been struggling with this tooth, a quick and effective decision had to be made.

_Findings

There were no general pathological findings. Clinically, we found a Grade I mobility in tooth #21, a mobile crown on tooth #21, and a bleeding on probing score of 3. The sulcus probing depth was 2 to 3 mm. The vertical percussion test was negative at this point (Fig. 1). The rest of the teeth exhibited no pathological findings.

The radiological control showed sufficient root filling. The crown was not optimally placed and the intra-radicular post was of insufficient length and diameter (Fig. 1). Our initial suspicion of inflammation at the root proved negative following a second X-ray.

Treatment focus

The replacement of the intra-radicular post and a new crown did not seem to be sufficient treatment. Owing to the caries under the crown, the crown lengthening necessary to establish adequate biological width and the patient's complaints regarding this region, any further effort to preserve this tooth made no sense to us. The aesthetic outcome was another reason to promote tooth extraction. Any further conservative therapy would have resulted in aesthetic deficiencies. The patient also desired an efficient solution that would put an end to the problems in this region. Furthermore, the adjacent teeth only had small fillings at the palatal surface and it would have been a pity to have to prepare them for prosthodontics. Also for this reason, the patient rejected prosthodontic treatment of the adjacent teeth.^{2-5,7}

Our decision was to extract the tooth and immediately place an implant in order to support the soft tissue, influence bone remodelling and offer a temporary tooth replacement without a flipper.^{6,3,7,8,9,10,1} As the maxillary anterior region is an aesthetically sensitive region, we planned for an immediate implantation with simultaneous guided bone regeneration (GBR).^{11,12} As for the prosthesis, we selected a biocompatible metal-ceramic crown for financial reasons.

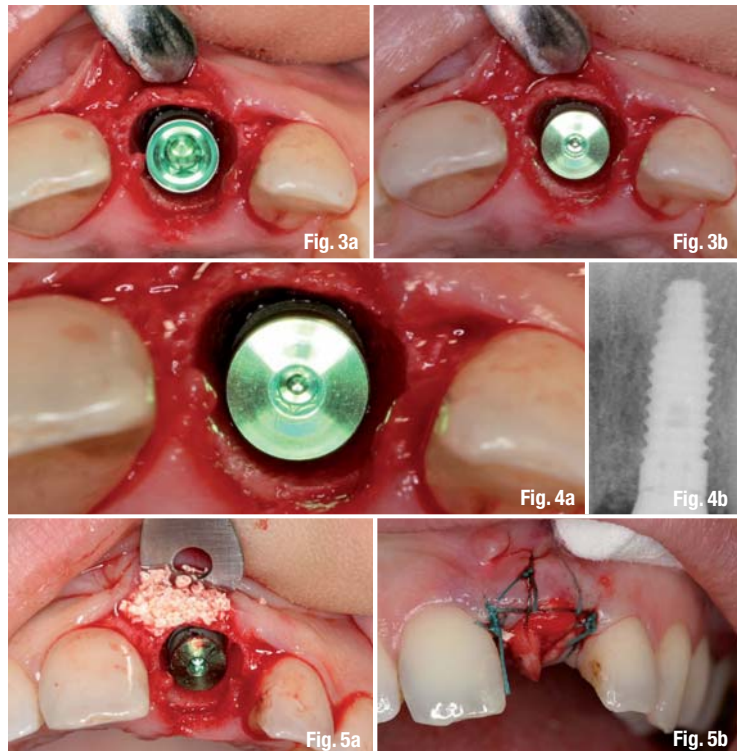
Treatment plan

Professional tooth cleaning and patient instruction

As a standard procedure, the patient received professional tooth cleaning before implantation in order to achieve optimal hygiene conditions. He also received behaviour and hygiene instruction and was encouraged to follow a good oral hygiene routine.

Extraction

The tooth extraction was performed as carefully as possible and the socket was decontaminated with chlorhexidine solution and tetracycline for ten minutes. Although mobile, the periodontal fibres were separated with a periosteal elevator. The tooth was mobilised with the same instrument until an atraumatic post extraction was possible. Together with the tooth, we managed to remove the apical cyst without needing to scale the socket. Careful inspection of the socket walls was necessary to prevent inflamed tissue affecting the GBR. There was also no perforation of the buccal plate (Fig. 1).^{9,13}

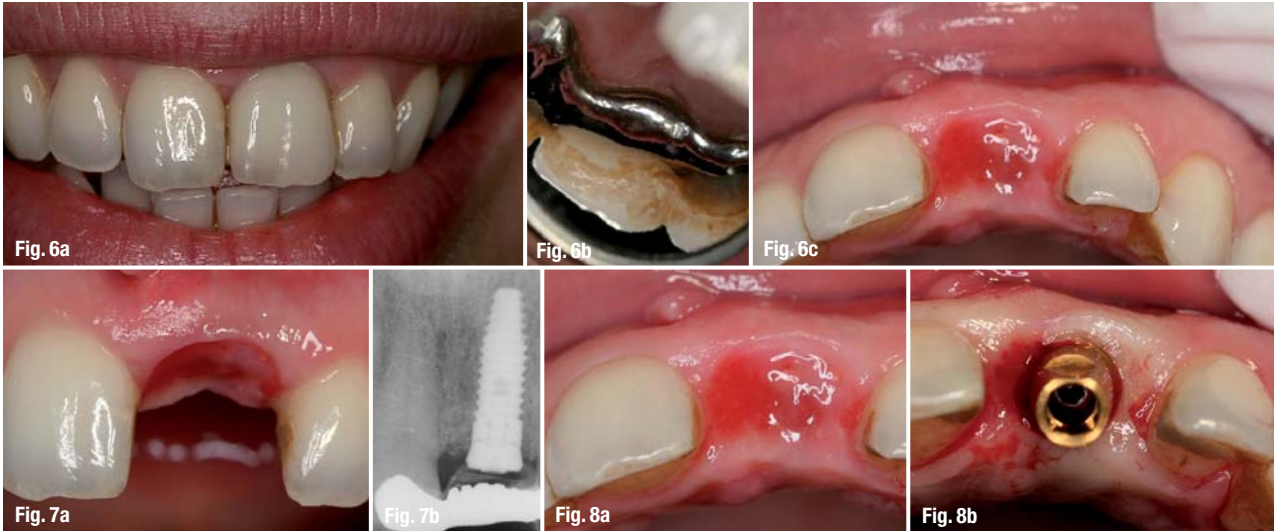


Implantation and guided bone regeneration

The implant we selected for this case was the internal hex Laser-Lok implant (BioHorizons), which is tapered with microgrooves at the implant neck. Our aim was to achieve maximal bone adaptation to the crestal portion and soft-tissue adaptation to the implant neck.^{14,15,10,17-19} We used a periodontal probe to inspect the socket. The socket was rinsed again with chlorhexidine solution before proceeding with the implantation. Apart from the final drilling, the drill sequence was performed with water irrigation. The last drilling was performed at 40 rpm/min and maximum torque in order to decrease the risk of ridge injury.

The gap width was 10.5 mm in the mesial-distal direction and 6 mm from the inner ridge in the oral-vestibular direction. The crestal thickness of the ridge walls was 0.5 to 1 mm (Figs. 2-4).^{6,7,9} Therefore, we decided to use a 4.6 mm implant with a length of 12 mm. Simultaneous to the implantation, we performed guided bone augmentation in order to fill the gap between implant and ridge and to influence bone remodelling during implant healing. The gap between the implant and buccal bone plate was 1.4 mm. Combined with the augmentation material (allograft using maxgraft, botiss) in this gap and on the buccal plate, we planned to preserve at least 2 mm buccally after bone remodelling.

One third of the implant was inserted. Augmentation followed and then we inserted the implant com-



pletely.^{20,6} In this way, we were ensured augmentation of the entire ridge and not only the crestal portion. For GBR, we used autologous bone extracted with a bone scraper (to preserve living osteoblasts) and non-resorbable hydroxyapatite (cerabone, botiss) for 3-D stability. The implant was placed sub-crestally at 1.5 mm in order to prevent under-coverage owing to bone resorption, which is inevitable following tooth extraction.²¹ Although the implant-neck design guarantees soft-tissue adaptation, we selected this kind of implant placement, since we feared unpredictable bone behaviour after so many years of continuous endodontic and inflammatory problems in this region.

Another advantage of this implant system is the all-in-one abutment, which supports positioning control and reverse planning for the prosthodontic treatment as an insertion aid. The implant was placed according to the best surgical position and the prosthetic position. A second all-in-one abutment was shortened to a length of 2 mm and used as a cover screw in order to achieve optimal soft-tissue support (Figs. 5 & 6). In this manner, we conditioned the soft tissue to form the final desired emergence profile.

Owing to the mild but unpredictable inflammation in region 21, we decided against a flap and primary closure of the operating area. The soft tissue was raised buccally in order to place a pericardium membrane (Jason, botiss). The membrane covered the

whole ridge up to the palatal wall, where it was secured between the gingiva and crestal ridge using a 4-0 Supramid horizontal mattress suture (S. Jackson). We placed a collagen fleece over the membrane to prevent proteolytic resorption of the exposed membrane. The fleece was secured with a 5-0 PROLENE criss-cross suture (ETHICON, Fig. 7).

Temporary crown

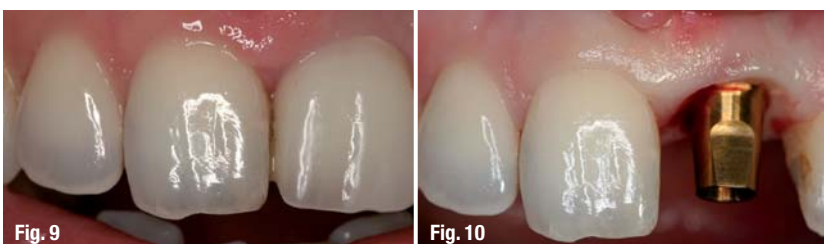Temporary treatment of the gap was crucial. Free granulation of the extraction wound resulted in a high risk of soft-tissue dehiscence. In order to fill the gap, to support and form soft tissue, and to rehabilitate the patient aesthetically, we trimmed the extracted tooth to form a pontic and attached it with flowable composite (Tetric EvoFlow, Ivoclar Vivadent) to the adjacent teeth. After soft-tissue coverage of the ridge, we attached a Maryland bridge to optimise aesthetics. The papilla support was perfect and the outcome until implant exposure was stabilised. The sutures were removed four weeks post-operatively and two weeks after the Maryland bridge had been attached, without having to remove it (Figs. 5, 6, 8 & 9).

Healing phase

During the healing phase, we followed a frequent recall pattern of one, two, three, four, eight, twelve and 16 weeks. In addition to hygiene instructions, the patient was informed about the importance of the control appointments. During the healing phase, there were no complications, inflammation or complaints from the patient.

Exposure

The implant was uncovered after 14 weeks. Owing to sufficient soft-tissue thickness on the labial side, we decided to uncover with a tissue punch. The tissue punch was 1 mm thick. The operation resulted in a soft-tissue height of 3 mm crestally up to the implant neck. The papillae were maintained, and labially the



contours of the bone and the soft tissue were harmonious and at optimum level aesthetically. These findings ensured a highly aesthetic outcome (Figs. 10 & 11).

Pre-prosthetic phase

At this point, we decided against a healing abutment. Assuming that implant transfer, abutment and healing abutment have the same emergence profile, we fabricated the final abutment after impression and inserted it with a temporary resin crown (Trim, Bosworth). The temporary crown had exactly the same form as the final crown and conditioned the tissue for the time needed to fabricate the final crown (Fig. 12).

Prosthetic phase

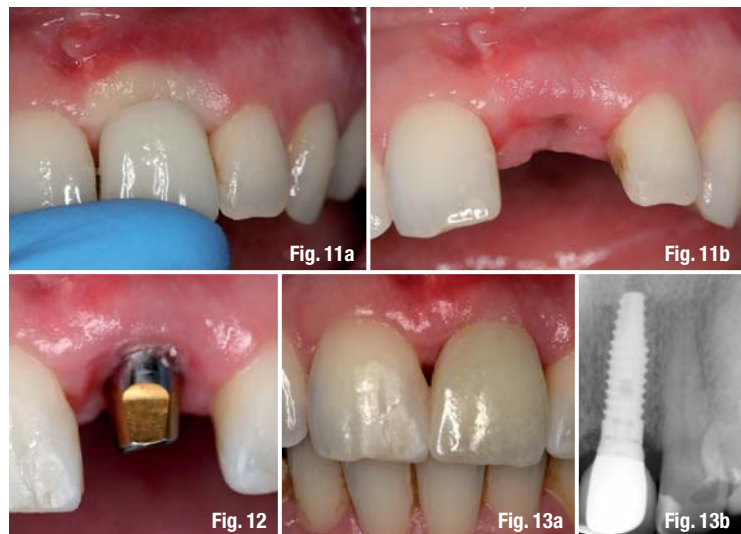
Two weeks after uncovering the implant, we performed the final crown fitting. The abutment length was 5.5 mm and the crown retention part had a length of 4.5 mm. The crown length was 8.5 mm and the distance between approximal contact and crestal bone was 4 mm (Fig. 13). The patient was pleased with the aesthetic outcome.

Recall appointments for clinical and radiological control took place at one week, as well as six, 12 and 18 months. At each appointment, stable conditions in the crestal bone and in the soft tissue were exhibited. At the 24-month follow-up, no recessions or clinical or radiological crestal bone resorption was apparent.

Discussion

Nowadays, we know that osseointegration works and we know how it works. We can also achieve predictable and repeatable results. The correct implant position is crucial for long-term success, and is both a surgical and a prosthetic parameter. No matter how well implants are inserted, grafted or osseointegrated, if the angulation and position are not beneficial for the prosthesis, the outcome will be neither aesthetic nor durable. The clinician must first decide where to place the abutment and decide upon the emergence profile before he performs the surgical part. As implantology becomes an increasingly important treatment option, osseointegration and a firm bite, as well as functional stability, aesthetic and long-lasting results, are more frequently demanded by the patients.

A crucial question has to be asked: now that aesthetics is becoming increasingly important, how much sense do conservative treatments make in cases such as the one described here? Is it better to extract a tooth causing ongoing problems at the right time, rather than trying to preserve it and losing bone and soft tissue? When we wait for too long, we lose bone and soft-tissue aesthetics and limit our implantological treatment options. In this case, extracting the tooth was the cor-



rect choice, as was placing the implant immediately. Seeking to influence bone remodelling by augmentation was also a good decision. Using an all-in-one abutment as a cover screw and scaffold for the soft tissue was also the only way to achieve an aesthetic outcome.

All these aspects, as well as correct positioning, prosthesis and recall, are factors that must be planned before surgery. Reverse planning is very important. If the planning is correctly structured, the surgical part entails only a drill sequence, especially when using computer guidance. Patients do not only want to eat with their teeth, but they want them to look good for a long time. This can only be achieved if we choose the right system for each patient, customise our operating protocol according to each individual situation, decide first where we want to place the abutment for perfect prosthetics and then manipulate the soft tissue without a scalpel. We can preserve the crestal bone by both adequate surgical bone treatments and soft tissue.

Each technique works well within its specific range of indication. The correct decision with regard to which technique to use, when and for which patient is the key to success. In addition, collaboration between surgeon, prosthetic specialist and technician is necessary to achieve the desired result.

_contact

implants

Dr Nikolaos Papagiannoulis

Heidelberg Clinic for plastic and
cosmetic surgery
proaesthetic
Brückenkopfstraße 1/2, 69120 Heidelberg

Tel.: +496221 6461-0
Fax: +496221 6460-20
www.proaesthetic.de